L'APPROCCIO AL TRATTAMENTO DEL PIEDE DIABETICO INFETTO

Dott.ssa Fabrizia Toscanella

Resp. Centro Prevenzione e Cura del Piede Diabetico

Villa Tiberia Hospital, Roma

GVM CARE & RESEARCH

LA CLINICA NEL DIABETE: INCONTRO TRA ESPERIENZE MUTLIDISCIPLINARI SID-AMD *Tivoli 30.9.17*

CONGRESSO PERIFERICO AMD - SID

LA CLINICA DEL DIABETE INCONTRO TRA ESPERIENZE MULTIDISCIPLINARI
Tivoli, 30 settembre 2017

la dr./sa TOSCANELLA dichiara di aver ricevuto negli ultimi due anni compensi o finanziamenti dalle seguenti Aziende Farmaceutiche e/o Diagnostiche:

- LILLY

Diabetic foot infections (DFIs) occasionally present as *cellulitis* or *post-traumatic* (including postsurgical) infections but are most commonly a consequence of *ulcerations* secondary to progressive peripheral polyneuropathy.

These neurological problems are commonly accompanied by arterial insufficiency and immunological disturbances.

Review: Diabetic foot infections: what have we learned in the last 30 years? *Ilker Uc¸kay a,b,, Javier Aragon-Sanchez ;* International Journal of Infectious Diseases (2015)

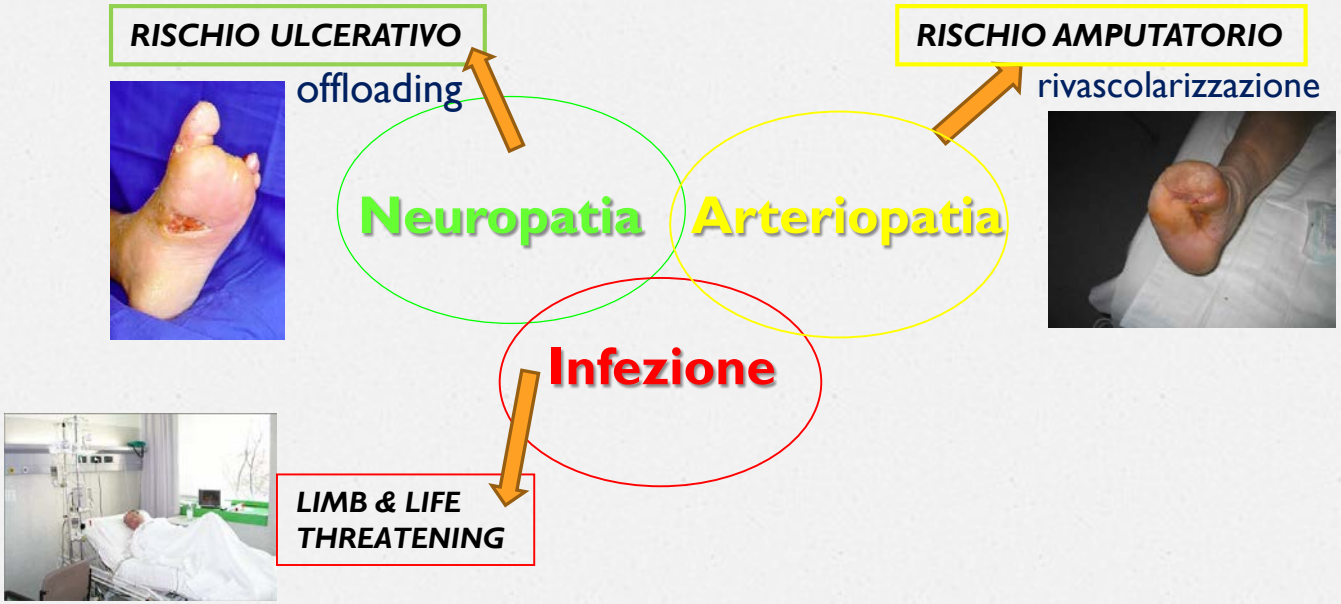

AUTONOMIC NEUROPATHY

sweating

Altered pH

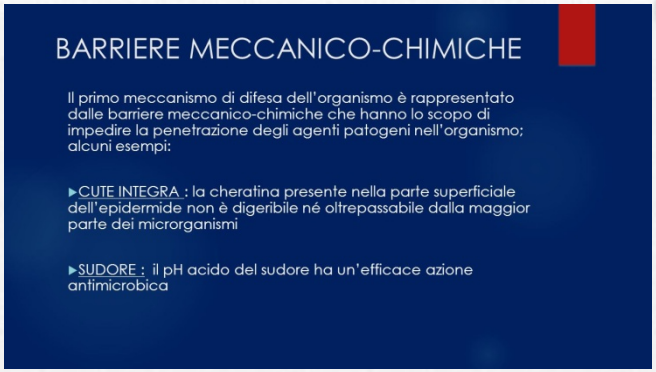

Alterated commensal flora

NEUROPATHY

NEURO-IMMUNOPATHY

two integrative supersystems that work together

NEURAL-IMMUNE AXIS

Key link:

•Sensory (unmyelinated nerve fibers – c fibers)

•Modified macrophages, mast cells and host defence cells

Major down-regulation *of bone marrow haemopoietic output*

Edmond

CLASSIFICAZIONE WIFI nel DFU
Wound, Ischemia, Foot, Infection

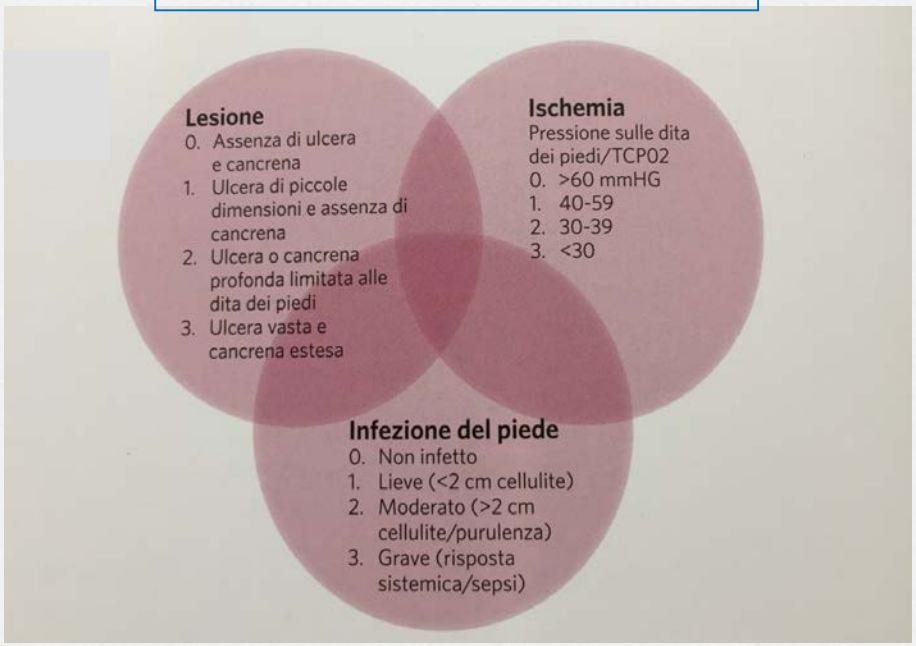

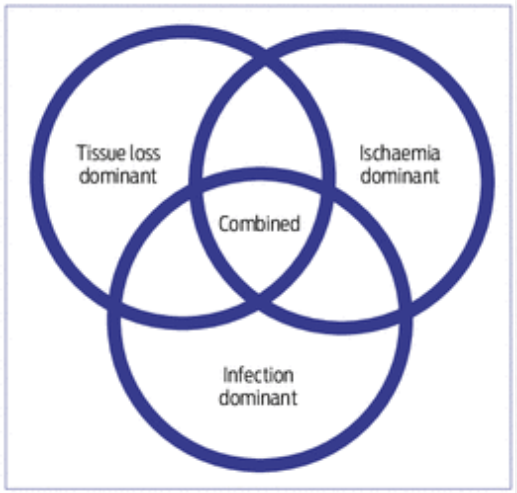

Fig 1. The three risk factors for amputation illustrated as three intersecting rings of dominance (adapted from Armstrong and Mills)[1]

Patients now are more often treated in the *ambulatory setting*, with *antibiotic regimens* that are more targeted, oral and shorter course, and with more conservative (but earlier) surgical interventions.

DF care is particularly aimed at preventing foot complications and includes *debridement of callus and necrotic tissue, nail care (especially with onychomycosis), the treatment of blisters, prescribing proper footwear, and fitting orthotic devices*. Once complications occur, however, the goal becomes AVOIDING AMPUTATION.

International Working Group on the Diabetic Foot (IWGDF) classification system

Table 1. The classification systems for defining the presence and severity of an infection of the foot in a person with diabetes developed by the Infectious Diseases Society of America (IDSA) and the International Working Group on the Diabetic Foot (IWGDF)

Clinical classification of infection (IDSA), with definitions	IWGDF grade (IDSA classification)
Uninfected: No systemic or local symptoms or signs of infection	1 (uninfected)
Infected:	
– Other causes of an inflammatory response of the skin should be excluded (e.g. trauma, gout, acute Charcot neuro-osteoarthropathy, fracture, thrombosis, venous stasis)	
– Infection involving the skin or subcutaneous tissue only (without involvement of deeper tissues and without systemic signs as described below) – Any erythema present extends <2 cm[1] around the wound – No systemic signs or symptoms of infection (see below)	2 (mild infection)
– Infection involving structures deeper than skin and subcutaneous tissues (e.g. bone, joint, tendon) or erythema extending >2 cm[1] from the wound margin – No systemic signs or symptoms of infection (see below)	3 (moderate infection)
– Any foot infection with the following signs of a systemic inflammatory response syndrome, as manifested by ≥2 of the following: •Temperature >38 or <36 °C •Heart rate >90 beats/min •Respiratory rate >20 breaths/min or $PaCO_2$ <32 mmHg •White blood cell count >12 000 or <4000 cu/mm or 10% immature (band) forms	4 (severe infection)

[1]In any direction.

DFI must be diagnosed clinically, with wound cultures reserved for determining the causative organisms and their antibiotic sensitivities

Expert opinion on the management of infections in the diabetic foot

Diabetic patient with a suspected foot infection

↓

- Cleanse, debride and probe the wound
- Assess neurological and vascular status of foot
- Assess for purulence or signs of inflammation
- Consider obtaining plain radiographs (or MRI)
- Obtain appropriate specimen(s) for culture
- Obtain other appropriate laboratory tests
- Assess any medical co-morbidities
- Determine if surgical consultation is needed
- Assess patient's psycho-social situation

↓

Classify the wound (if infected)

↓

Mild/Moderate

- Assess the need for inpatient treatment
- Review any available microbiological data
- Select initial antibiotic regimen (consider oral, relatively narrow-spectrum)
- Select appropriate wound care (dressings, off-loading)
- If treated as outpatient, set up return visit, consultations

↓

If not hospitalized, reassess in 2-4 days, or before earlier if substantially worsens

Severe

- Hospitalize the patient
- Attend to fluid, electrolyte, metabolic needs
- Obtain blood cultures
- Select empiric, broad-spectrum parenteral antibiotic regimen (consider MDROs)
- Arrange for urgent surgery, if needed

↓

Reassess clinically at least once daily; check inflammatory markers as needed

Assess clinical signs/symptoms of infection

Improving

- Consider de-escalating antibiotic regimen (narrower spectrum, less toxic, expensive)
- Reassess ~ weekly until Infection resolves
- If fails to resolve or relapses consider deep abscess, osteomyelitis or resistant pathogen

Not improving/worsening

- Review culture & sensitivity results
- Assess patient's adherence to treatment regimen
- Reassess wound care, need to hospitalize
- Consider further imaging
- Re-culture wound

Improving

- Switch to appropriate oral antibiotic regimen
- Follow-up as outpatient

Not improving/worsening

- Define extent of tissue involved (MRI, surgical exploration)
- Review culture & sensitivity results; cover all isolates
- Consider broadening antibiotic spectrum
- Reassess need for surgery, including revascularization, or amputation

---

MDRO= multi-drug resistant organism

2012

Figure 1. Approach to the infected diabetic foot

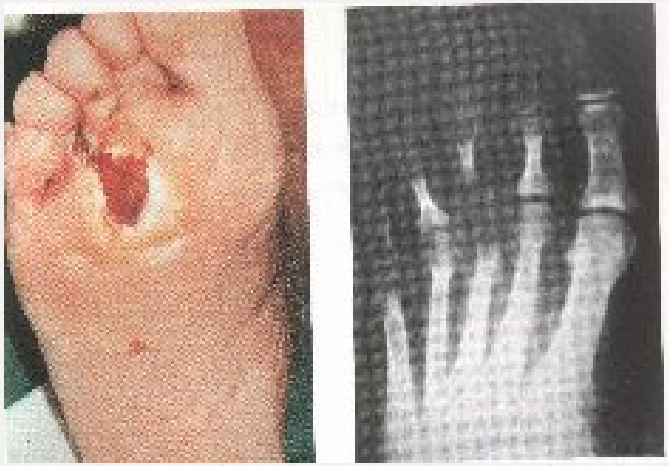

Diabetic foot osteomyelitis is a major risk factor for amputation.

DF **OSTEOMYELITIS** usually occurs by the contiguous spread of infection from overlying soft tissue.

PROBE-TO-BONE +

Based on several reports,
the *sensitivity* ranges from about 60% to 87%,
specificity from 85% to 91%, and *positive predictive value* from 87% to 90%,
but the *negative predictive value* is only 56–62%.

Table 1. Risk Factors for Osteomyelitis in Patients with Diabetic Foot Infection

Appearance of a swollen, deformed red toe (also called sausage toe)
Bone visible or palpable on probing
Infected ulcer with an erythrocyte sedimentation rate of more than 70 mm per hour
Nonhealing ulcer after a few weeks of appropriate care and off-loading of pressure
Radiologically evident bone destruction beneath ulcer
Ulcer area greater than 2 cm^2 or more than 3 mm deep
Ulceration presents over bony prominences for more than two weeks
Ulceration with unexplained leukocytosis

Table 2. Common imaging features of diabetic foot osteomyelitis

Plain radiographs
  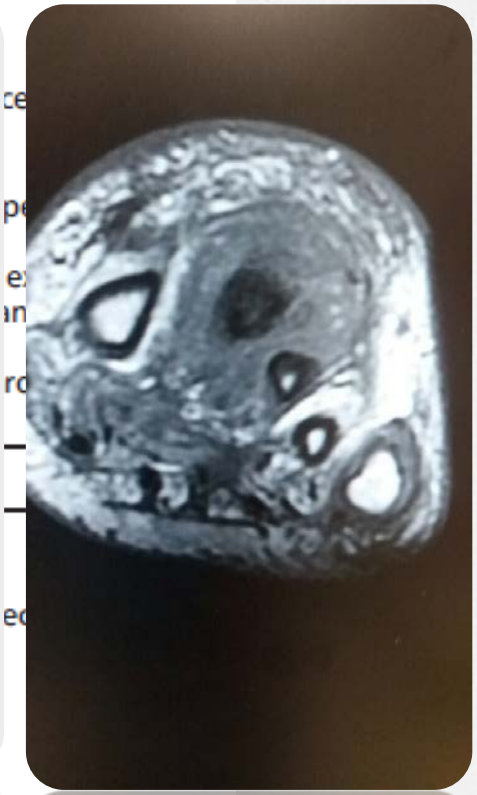
○Soft tissue mass ○Sinus tract formation ○Adjacent soft tissue inflammation or oedema For both modalities, bony changes are often accompanied by contiguous soft tissue swelling.

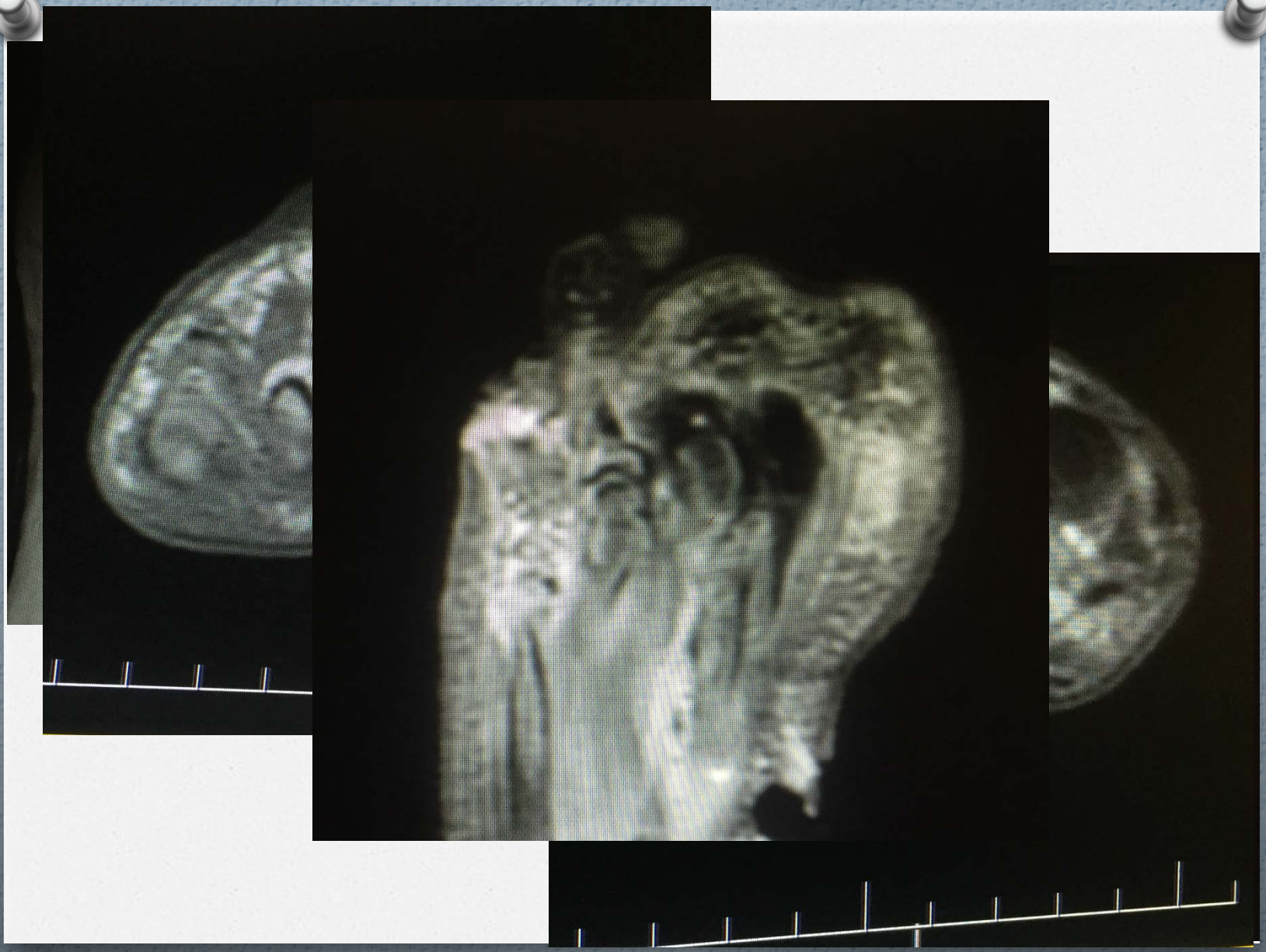

A recent prospective study that enrolled 110 patients reported that **PET/CT scan** had a sensitivity of **81%,** specificity of 93%, positive predictive value of 78%, negative predictive value 94% and accuracy of **90%,** which was somewhat better than a simultaneous MRI .

While the data on this new procedure are limited, there seems to be a place for CT (especially if combined with PET) scans when MRI is unavailable or contraindicated.

The criterion standard for diagnosing osteomyelitis remains a culture of bone and, when possible, histopathological examination.

Recent prospective trials have shown that culture results of soft tissue or of needle puncture specimens of bone often fail to correlate with transcutaneous or operative bone specimens.

Medical treatment allows remission in 53-82% of cases (6-12 weeks). However, the optimal duration of antibiotic therapy remains controversial as a validated marker of osteomyelitis remission is lacking. The last studies suggest that **WBC-SPECT/CT** could **predict remission at the end of antibiotic treatment.**

Diabetologia. 2017 **Application of white blood cell SPECT/CT to predict remission after a 6 or 12 week course of antibiotic treatment for diabetic foot osteomyelitis.** Vouillarmet J
Diabetologia. 2017 **Osteomyelitis of the foot: non-surgical management, SPECT/CT scanning and minimising the duration of antibiotic use.** Jeffcoate WJ

Contrary to the teaching of 30 years ago, there are now reports of hundreds of cases of DIABETIC FOOT OSTEOMYELITIS treated ***without surgery***, with remission rates of 60% to 70%; one recent randomized controlled trial showed similar cure rates for medical and for primarily surgical therapy….

Regarding ***the duration*** of antibiotic therapy, a systematic review of the treatment of osteomyelitis in patients with and without diabetes found that there was *no evidence* that antibiotic therapy for *more than 4–6* weeks improves outcomes compared with this duration

Published randomized controlled DFI trials have failed to show *superiority of any particular antibiotic agent or route of administration*. Several systematic reviews of antimicrobial treatments for DFI have concluded that ***there is insufficient evidence to recommend any particular antimicrobial agent or route of administration***.

Review: Diabetic foot infections: what have we learned in the last 30 years? *Ilker Uc¸kay a,b,*, Javier Aragon-Sanchez c, Daniel Lew a, Benjamin A. Lipsky* International Journal of Infectious Diseases 2015

Some studies suggest that **HBOT** facilitates wound healing and decreases rates of lower extremity amputation in diabetic patients with a foot ulcer or postsurgical amputation wound, but most experience is retrospective and non-comparative.

There are, however, *no published data directly related to the effect of HBOT on infectious aspects (either soft tissue or bone) of the diabetic foot.*

Oliveira N, Rosa P, Borges L, Dias E, Oliveira F, Cassio I. **Treatment of diabetic foot complications with hyperbaric oxygen therapy: a retrospective experi-ence.** Foot Ankle Surg 2014;

Prompt diagnosis of abscess and distinction between bone and soft tissue infection are the prime goal of imaging modalities.
Plain radiography is most common choice of radiological investigation owing to its low cost and wide availability but has got poor sensitivity and specificity rate.

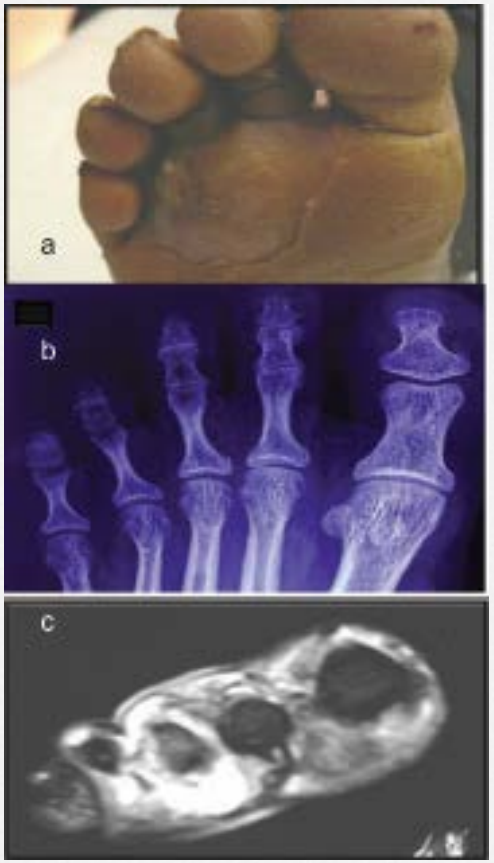

*Any foot compartment affected by infection should be **opened quickly** to reduce the compartmental pressure*

MRI is a sensitive and accurate imaging modality for evaluation of diabetic foot and for planning proper treatment and the MRI correlates significantly with the ***surgical finding***.

Diagnostic Accuracy and Surgical Utility of MRI in Complicated Diabetic Foot *Journal of Clinical and Diagnostic Research*. 2017 M.Mahendra, R.Singh,

Anatomical principles

It is very important to understand that the foot is divided into rigid compartments. This has two implications for the surgeon:

1. Compartmental pressure may increase as a consequence of the infection and tissue damage may be more extensive than expected. Ischemic necrosis will add to the damage promoted by bacteria and host defenses. The compartment that is affected by the infection should be exposed in an efficient and expedited way in order to diminish the compartmental pressure.
2. The surgeon needs to be aware and have a high index of suspicion regarding the initial entry point of infection.

Figure 1 demonstrates a clinical view of the plantar aspect of the foot in a diabetic patient with r
fourth toe and the division of the foot into
compartments. The floor of the compartme

plantar aponeurosis which is attached to the calcane
and extends distally to the toes (Fig. 2, in blue). T
plantar aponeurosis is the outermost fascia and rep
sents the anatomical layer located beneath the subcu
neous tissue. The medial and central plantar f
compartments are separated by the medial intermuscu
septum, which extends from the medial calcaneal tub
osity to the first metatarsal head. The central and late
compartments are separated by the lateral intermuscu
septum, which extends from the calcaneus to the fi
metatarsal head (Fig. 1, yellow lines). The med
compartment contains the flexor hallucis brevis, abduc
hallucis and flexor hallucis longus tendons. The cent
compartment contains the flexor digitorum brevis, lun
rical muscles, flexor digitorum longus tendons a
quadratus plantae muscle. The lateral compartme
contains the flexor digiti minimi brevis and abduc

Fig. 1. Plantar compartments of the foot.

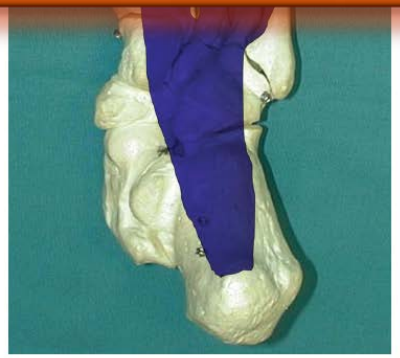

Fig. 2. Plantar aponeurosis.

PROGRAMMA OPERATORIO DI MASSIMA

CONSENSO INFORMATO!

The major aims of SURGERY in DFIs are **to evacuate pus, remove necrotic tissue, and minimize the risk of further spread**.
Bad outcomes are often related to a delayed diagnosis, leading to *extensive destruction of the soft tissue*

The optimal timing of surgery for DFI is not well defined, but **prompt surgery**, including **revascularization when necessary**, may reduce the need for above-ankle amputations.

The rate of success, including avoiding lower extremity amputation, in DFIs, depends on **the approach** taken by the treating surgeon, which often reflects his or her *experience and skills.*

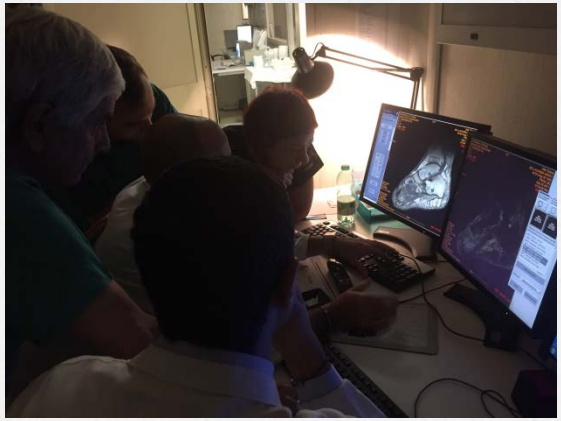

For patients with wet gangrene or sepsis, a **two-stage amputation** (*initial guillotine with later revision*) may lead to better primary stump healing than a one-stage procedure.

Table 1
Key changes in the knowledge and management of diabetic foot infections in the last 30 years—summary of the authors' views

Research field	1985	2015
Pathogens	Methicillin-susceptible *Staphylococcus aureus*, streptococci, *Enterobacteriaceae*	More multidrug-resistant organisms (MRSA, ESBLs) Predominance of Gram-negative pathogens in (sub)tropical climates
Microbiological diagnosis	Standard cultures, usually of swab specimens	Aerobic and anaerobic cultures of tissue specimens (soft tissue and bone) Molecular microbiology (e.g., PCR) Metagenomics
Imaging	Plain X-rays; scintigraphy (bone, leukocyte scans)	MRI; SPECT/CT; PET/CT
Antibiotic agents	Penicillins; 1st to 3rd generation cephalosporins; some 2nd generation fluoroquinolones	4th/5th generation cephalosporins; carbapenems; 3rd/4th generation fluoroquinolones; linezolid; daptomycin
Route of administration and site of treatment	Initial (sometimes prolonged) intravenous administration, usually in hospital	Mostly oral (sometimes after a brief intravenous course), even in the presence of vascular disease or osteomyelitis; some topical; outpatient except for severe infections or complex treatments
Spectrum of antibiotic therapy	Relatively broad (directed at Gram-positive and Gram-negative pathogens)	Very broad empiric therapy for severe infections; more targeted for mild/moderate infections and for definitive therapy
Duration of antibiotic therapy	Many weeks for soft tissue infections; ≥6–12 weeks for bone	1–2 weeks for soft tissue infections; 4–6 weeks for osteomyelitis
Surgical approach	Aggressive (ablative) therapeutic surgery; inpatient treatment	More conservative (tissue sparing) therapeutic (even for osteomyelitis) and preventive surgery; corrective surgery; often in outpatient facilities and specialized diabetic foot centres
Revascularization	Open vascular surgery	More percutaneous angioplasty and distal bypasses, including infragenicular
Management	Mostly individual, empirical approaches	Clinical guidelines based on systematic reviews; multidisciplinary teams, especially including podiatry; clinical pathways; some behavioural sciences
guidelines	Individual recommendations and practices on the hospital level	national guidelines; validation of guidelines
Adjunctive treatments	Stimulation with growth factors; platelet-rich products; larval biotherapy (maggots)	Hyperbaric oxygen therapy; granulocyte-stimulating factors; research in stem cell and bacteriophage therapies; microbiome concepts
Dressing	Simple dressings, with separate use of disinfection agents	More hydrofibre and silver-containing dressings; studies with topical antibiotics embedded in dressings
Scientific publications	Mostly case series	More prospective randomized trials, multicenter studies, and evidence-based (Cochrane) meta-analyses

Grazie


Soleus
Gastrocnemius tendon
Tendo calcaneus
Tibia
Flexor hallucis longus
Flexor digitorum longus
Tibialis posterior
Calcaneus
Tibialis anterior
Tuberosity of navicular
Fibularis (peroneus) longus
Fibularis (peroneus) brevis
Quadratus plantae
Flexor digitorum longus
Slip from flexor hallucis longus
Flexor hallucis longus
Lumbricals